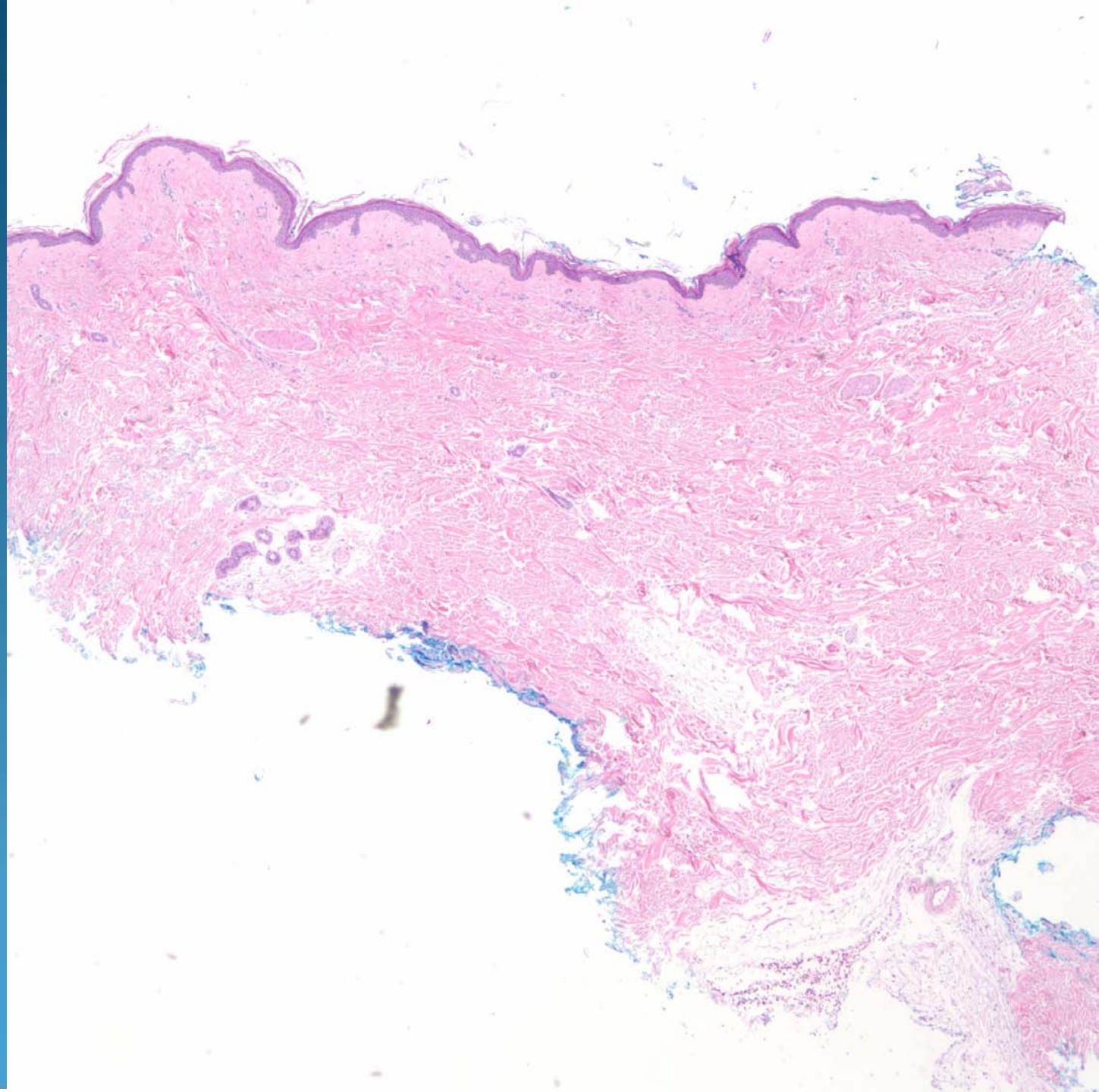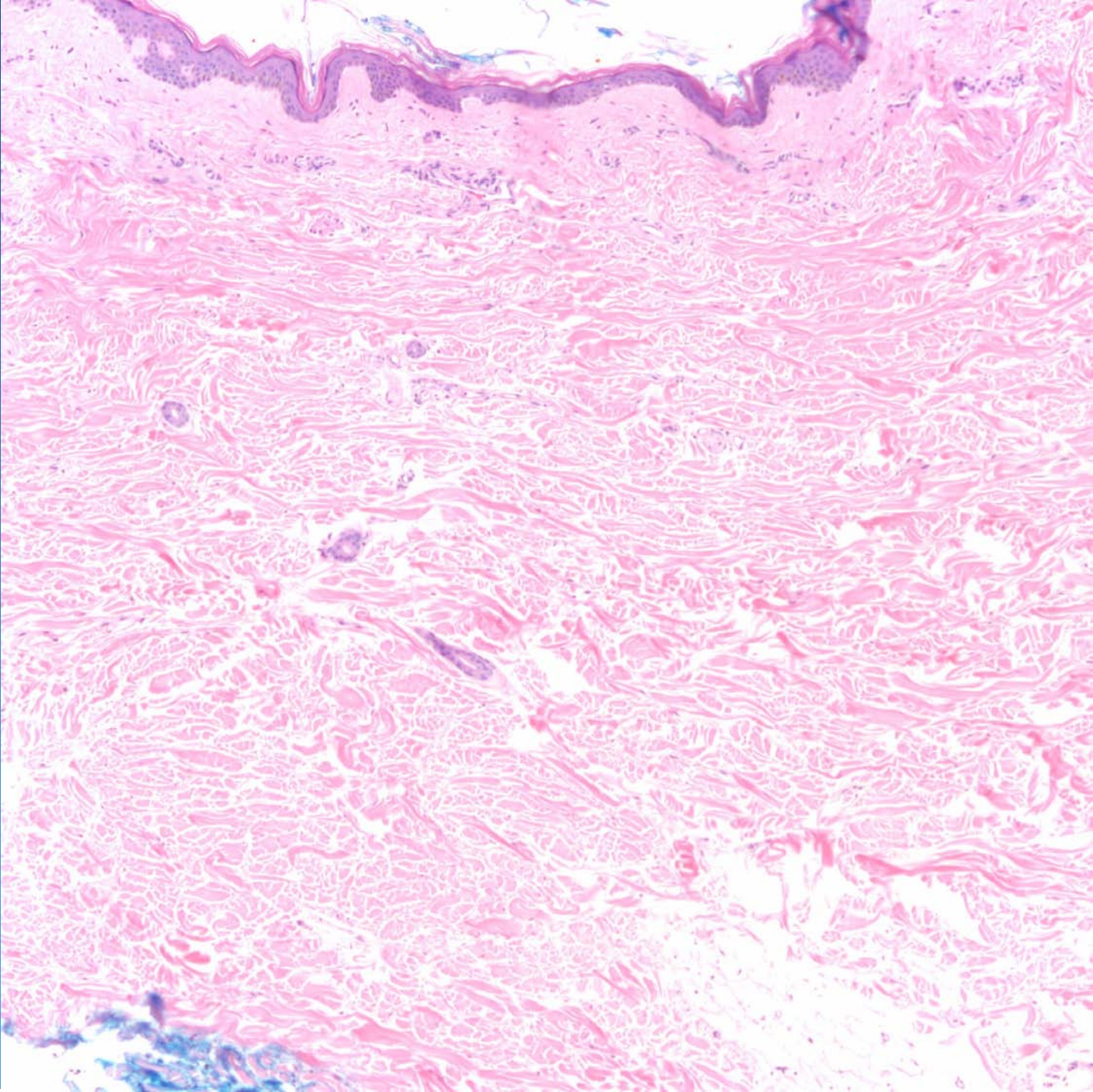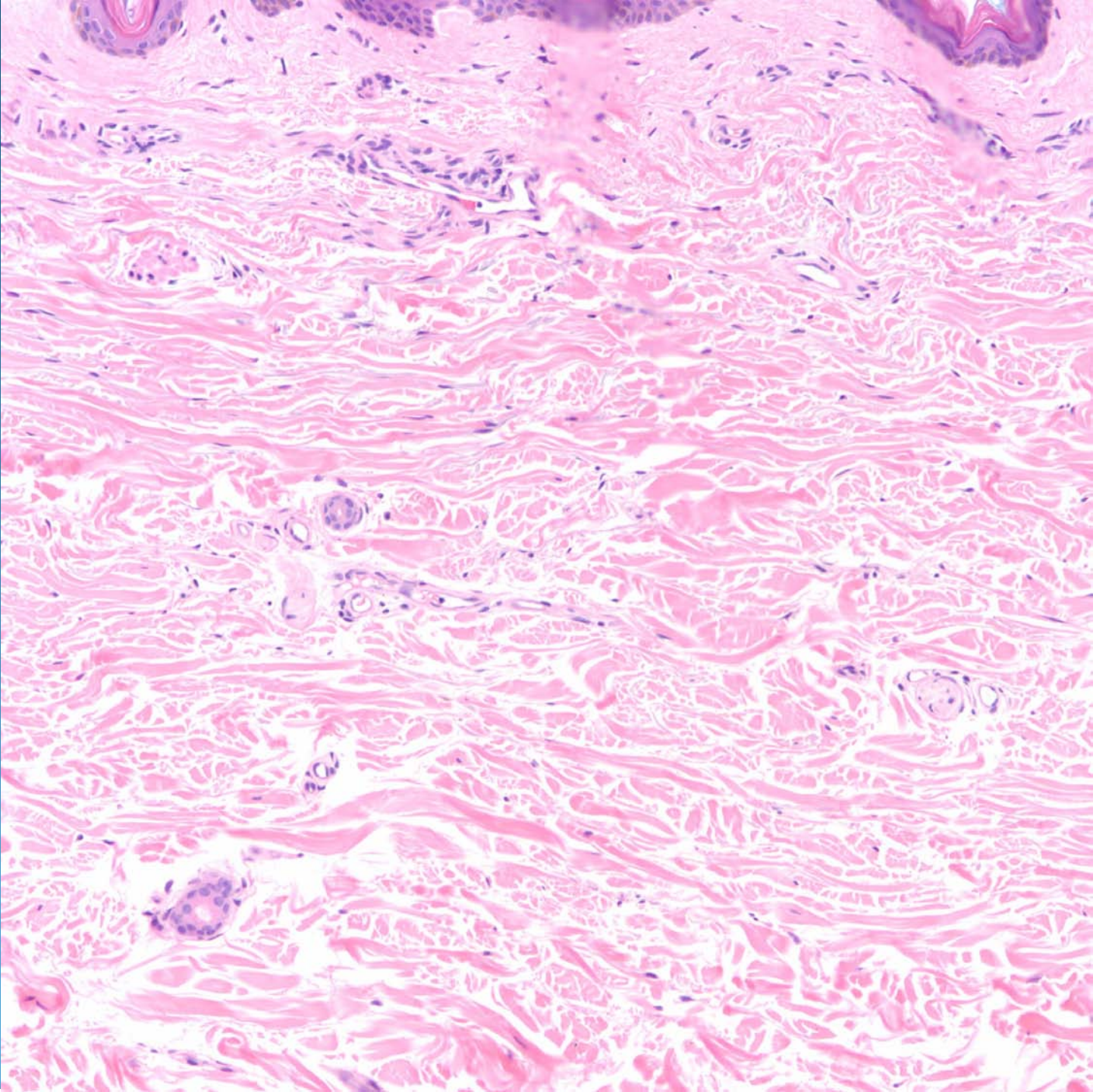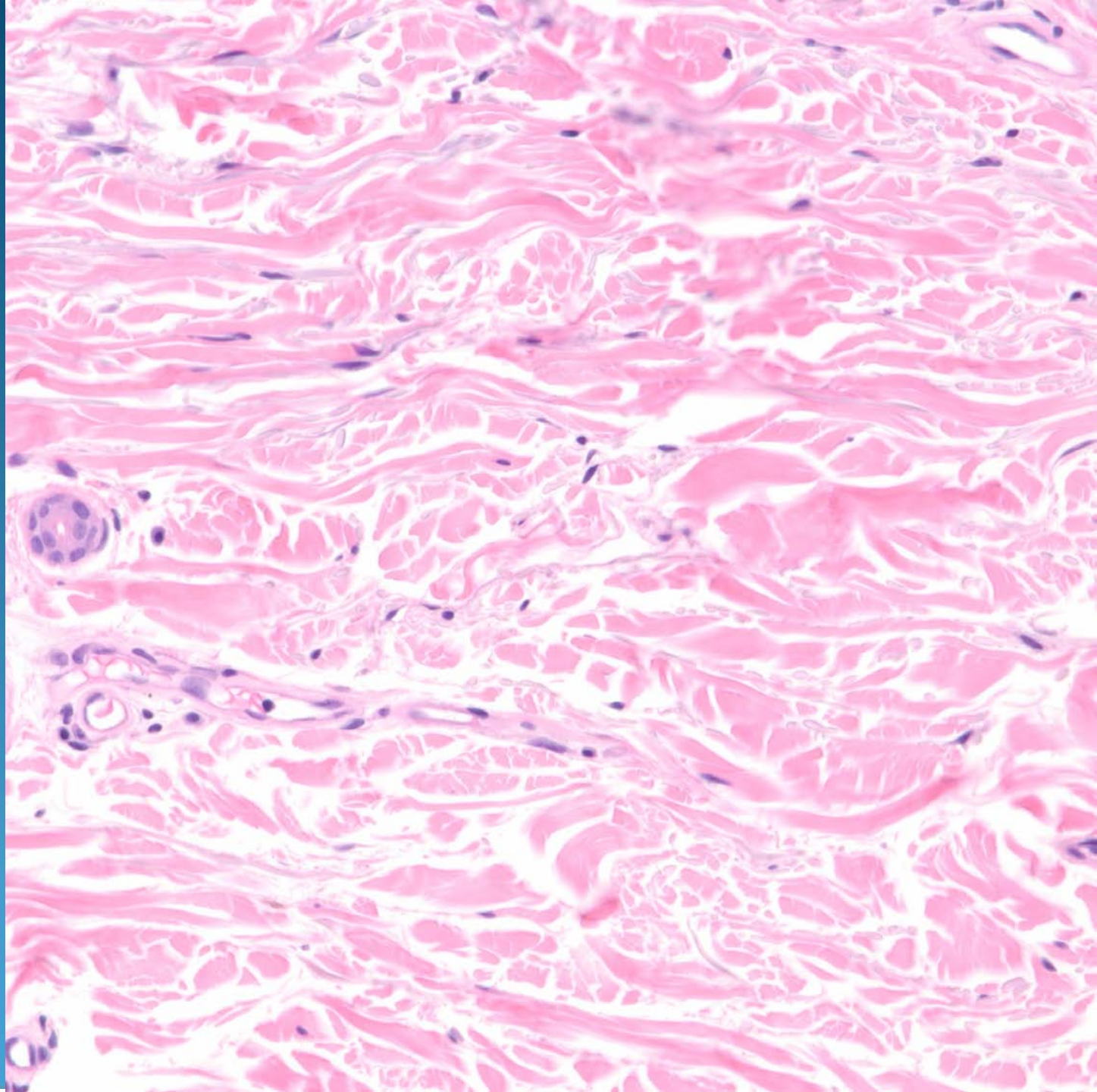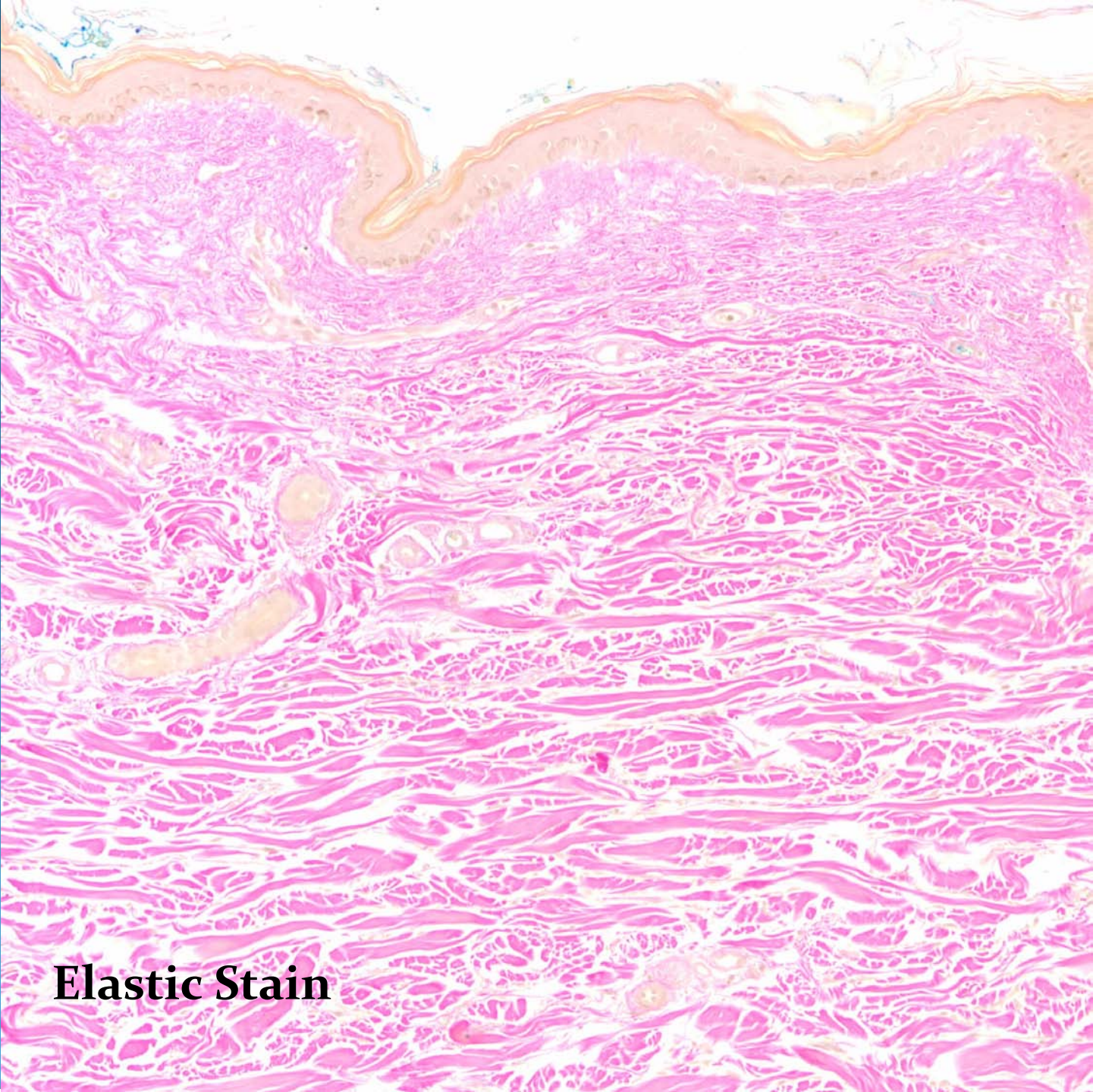


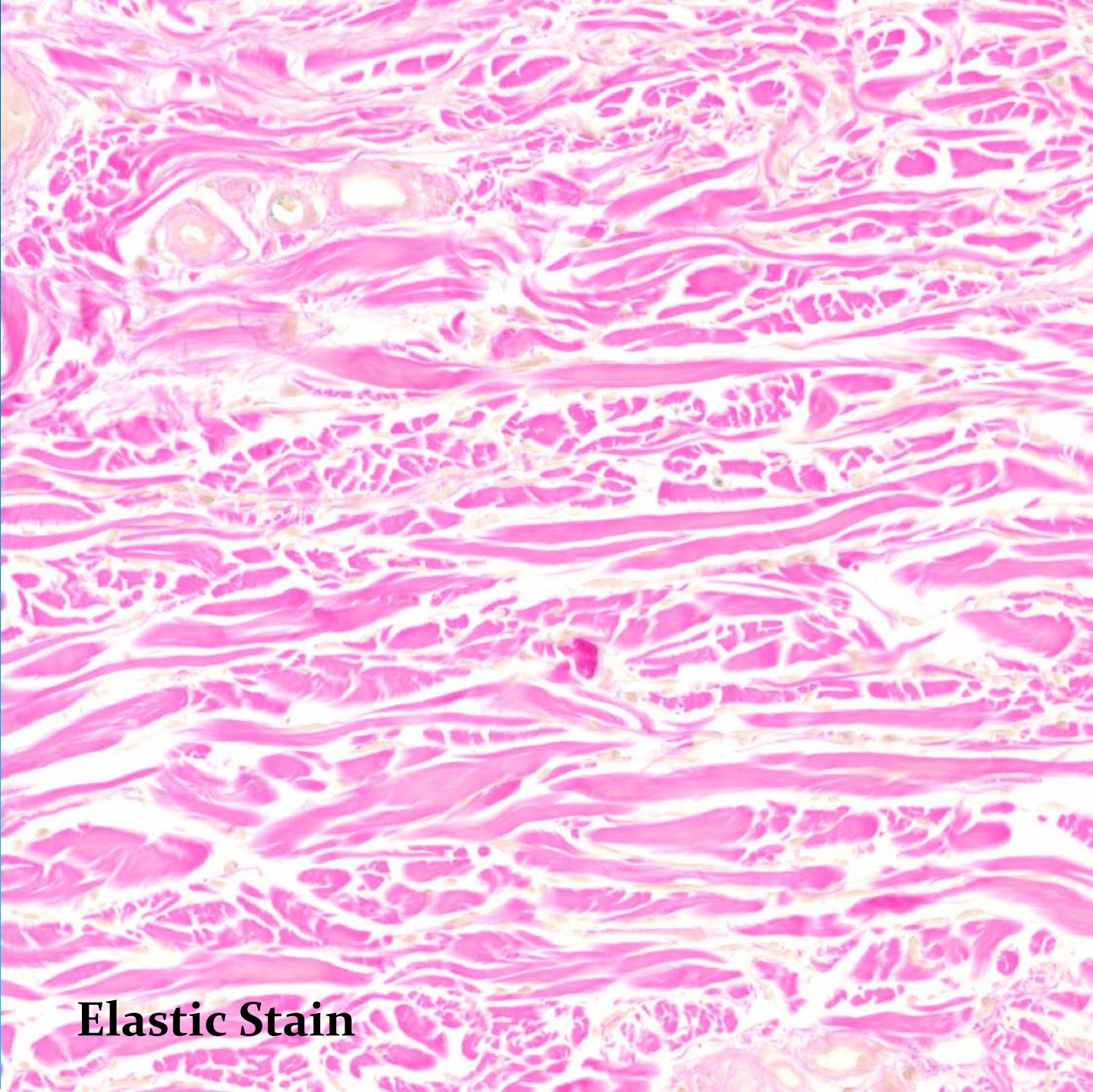Cutis Laxa

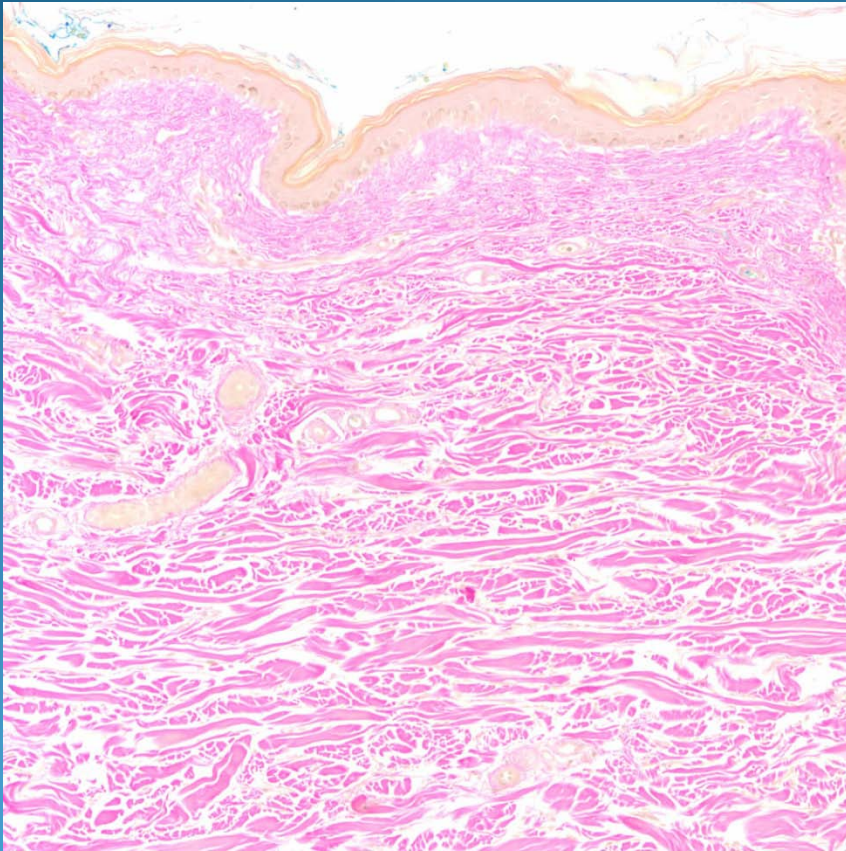


Elastic Stain



Elastic Stain

Pearls



- Invisible dermatosis-clinical pathological correlation
- May have slight decrease in dermal thickness
- Need elastic stain (VVG) to show near complete absence of elastic fibers
- DDX: Primary vs. secondary